

Introduction

Over the past decade there has been a dramatic increase in the use of negative pressure wound therapy (NPWT). This advanced technology has revolutionised care for many patients with chronic and acute wounds^{1,2}. Widespread adoption of NPWT over the past 15 years has been driven largely through favourable clinical experience rather than randomised clinical studies or thorough scientific knowledge. However, it now seems that understanding the mechanism by which negative pressure affects the wound bed may allow the clinician to choose the right dressings and pressure settings for NPWT to obtain optimal effects with minimal complications.

*Authors: Malmjö M, Borgquist O.
Full author details can be found on page 4.*

What is NPWT?

In 1989, Chariker described a gauze-based negative pressure drainage therapy for healing wounds³. Previous use of gauze-based NPWT in the Soviet Union has been described by Miller⁴. Negative pressure therapy for the treatment of wounds was popularised by Argenta and Morykwas in 1997, who described the use of subatmospheric pressure through an open-pore structure polyurethane foam to expedite wound healing and laid the foundations for a scientific understanding of the therapy^{5,6}.

Today, NPWT is used for the clinical treatment of many wound types¹, including orthopaedic trauma⁷, soft tissue trauma⁸, skin grafts⁹, pressure ulcers¹⁰, venous leg ulcers¹¹, diabetic foot ulcers¹², burns¹³, surgical infections¹⁴, and management of other major surgical wounds^{15,16,17}.

NPWT uses a closed drainage system to apply controlled suction (vacuum) to a wound bed. The wound is first filled with a wound filler (gauze or foam) to allow pressure to be distributed evenly to the wound bed. The wound is then sealed with an adhesive plastic drape and the drain is connected to a vacuum pump. Wound fluid is sucked out through the drain and collected in a canister.

What are the NPWT mechanisms of action?

The mechanisms by which NPWT is known to accelerate wound healing are as follows: NPWT creates a moist environment¹⁸, drains exudate^{5,6,19}, reduces tissue oedema²⁰, contracts the wound edges^{5,6,19}, mechanically stimulates the wound bed²¹⁻²³, alters blood flow in the wound edges^{6,24-26}, and stimulates angiogenesis^{27,28} and the formation of granulation tissue⁶. NPWT can offer protection against infection as the wound is sealed; in addition, the need for less frequent dressing changes may further reduce the risk of contamination. The biological effects of NPWT on the wound bed depend on the type of dressing and the negative pressure setting applied (described below).

What is the wound interface?

The dressing that is in direct contact with and therefore interacts with the wound bed is called the **wound interface**. The wound interface may be the **wound filler** (commonly either an open-pore structure polyurethane foam or saline-moistened gauze) or a low-adherent **wound contact layer** that is placed underneath the wound filler to cover the wound bed (Figure 1).

The properties of the wound interface determine most of the effects of NPWT on the wound bed. The interaction between the wound interface and the wound bed has been described in detail for foam and gauze^{21,29}. Both these wound fillers cause a mechanical effect on the wound²¹. The tissue surface is stimulated by the structure of the wound dressing. This will trigger the cells to divide to rebuild and strengthen the tissue.

What is the function of the different wound interfaces?

Wound filler material (commonly foam or gauze)

The function of the wound filler is to deliver negative pressure to the wound bed. Experimental studies indicate that pressure is equally well distributed through foam as it is through gauze²². The suction force generated by the negative pressure leads to active drainage of exudate from the wound. This will lead to a reduction in various compounds that are inhibitory to wound healing, such as proteolytic enzymes and metalloproteinases^{30,31}. It is important to place the wound filler in direct contact with all

NPWT settings and dressing choices

made easy



areas of the tissue where the NPWT effect is desired.

Wound contact layer

A non-adherent wound contact layer is placed underneath the wound filler when the clinician anticipates complications^{32,33}. A wound contact layer may be placed over vulnerable structures³³, but also over the wound bed itself since it is believed to protect from ingrowth of granulation tissue into the wound filler. Wound bed tissue has been shown to grow into foam, but not into gauze³⁴. The complications associated with ingrowth into foam are as follows:

- **pain during dressing changes as the ingrown tissue is torn away from the wound³⁵. Pain often needs to be treated vigorously^{36,37}**
- **wound bed disruption and mechanical tissue damage as foam is torn from the wound bed during dressing changes**
- **pieces of foam may become stuck in the wound bed and, if left in the wound, will act as foreign bodies that may hinder wound healing.**

What evidence exists for the use of these different wound interfaces?

To date, the scientific evidence on the biological effect of NPWT on the wound bed has concentrated on the use of either polyurethane foam or gauze as wound fillers^{21,34,38}. It must be remembered that in clinical practice, foam for NPWT is likely to be combined with a non-adherent wound contact layer. Even though it is well known that negative pressure is transduced through commonly used wound contact layers^{39,40}, studies that formally examine the effects of a combined foam and non-adherent contact layer on the wound bed and granulation tissue formation are still not available.

How do we choose an appropriate interface dressing?

Paglinawan *et al* demonstrated that the use of either gauze or foam result in increased granulation tissue formation³⁸. In a case series, the rate of wound healing under NPWT using

gauze was similar to that for foam⁴¹. However, studies are now emerging showing that the amount and character of granulation tissue formed may differ between the two dressings. The use of foam as a wound interface in NPWT produces thick, hypertrophic granulation tissue^{21,34,42}. Gauze under NPWT results in less thick but dense granulation tissue^{21,34}.

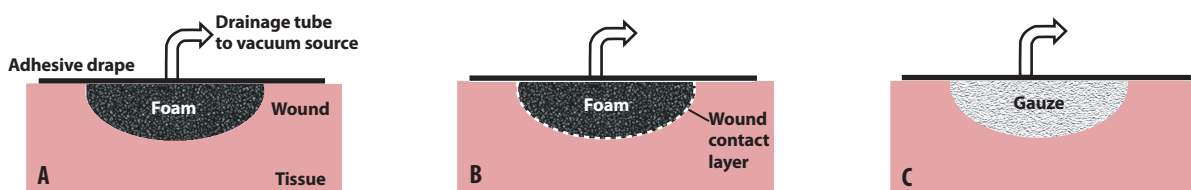
Foam as interface

The thick granulation tissue generated under foam during NPWT^{34,42} may sometimes be advantageous. However, it may also lead to problems such as fibrosis, which may result in scarring and subsequent contractures as the wound heals⁴².

Foam may be a good choice when treating wounds that benefit from thick granulation tissue and where scarring does not pose a problem, for example in fasciotomy wounds in upper or lower limb compartment syndrome where contraction is beneficial^{16,43}. In acute wounds with large tissue loss, foam may be a bridging therapy that contracts the tissue so that the wound edges are pulled together^{7,8}.

Figure 1 NPWT dressings

The **wound interface** may be either a **wound filler**, typically comprising foam (A and B) or gauze (C) or a non-adherent **wound contact** layer that is placed underneath the foam (B) to protect vulnerable structures or hinder ingrowth of granulation tissue into the wound filler.



Gauze as interface

Gauze is often used because of its conformability and ease of application to large and irregular wounds⁴⁴. Gauze has become popular among some plastic surgeons for wound-bed preparation before grafting⁴⁵. Gauze may also be a good choice when the cosmetic result is of greater importance, or in cases where scar tissue may restrict movement, for example over joints. During NPWT, the wound filler is pushed into the wound and it is suggested that the technique of using gauze under negative pressure can tamponade superficial bleeding⁴⁶.

Gauze is a good wound filler, especially when circumstances are extreme. The use of gauze in NPWT is described by Jeffery *et al*, 2009, when treating wounds to military personnel caused by landmines and other explosive devices⁴⁴. There are no reported problems with ingrowth of granulation tissue into gauze in NPWT³⁴ and therefore no wound contact layer is needed. It is important to note that nearly all gauze used in NPWT has been a particular type of cotton gauze (Kerlix AMD)⁴¹, which may provide antimicrobial control since it is impregnated with polyhexamethylene biguanide (PHMB).

How often should the NPWT dressing be changed?

The frequency of dressing changes required will depend on the type of dressing used but also the wound type. The usual recommendations are to change foam dressings every 48 hours^{47,48}. This is because the foam needs to be changed before ingrowth becomes a problem⁴⁹.

For gauze or a non-adherent wound contact layer, ingrowth is unlikely and dressing changes can probably be less frequent. It is currently recommended that gauze dressings are changed two or three times a week⁴¹.

What level of negative pressure should be used?

What pressure is the gold standard?

There are currently no detailed clinical guidelines regarding the adjustment of negative pressure levels to suit the individual wound. The most common pressure level used (-125 mmHg) is based on a limited study on pigs carried out in 1997⁶. These high levels of negative pressure can sometimes cause pain and therefore need to be reduced^{48,37}.

We know from preclinical studies that the maximum biological effects on the wound edges, in terms of wound contraction⁵⁰, regional blood flow⁵¹ and the formation of granulation tissue^{21,34}, are achieved at -80 mmHg. In addition, clinical studies have shown that negative pressure levels below -125 mmHg have resulted in excellent wound healing⁵². A series of clinical cases found that wound healing was similar when using -125 mmHg and -75 mmHg⁴⁸.

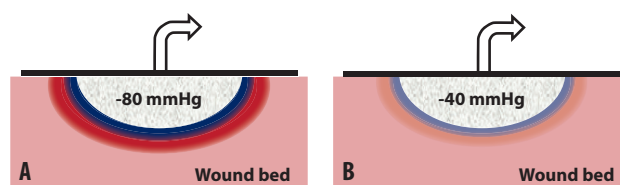
What pressure may be used if there is pain or a risk of ischaemia?

Blood flow is known to be decreased in the most superficial layers of the wound bed tissue (0.5cm from the wound edge) and increased in deeper layers of the tissue (2.5cm from the wound edge)^{25,26,51,53} (Figure 2). The decrease in blood flow is a result of the wound dressing being pushed into and compressing the tissue⁵⁴. In a wound that is not at risk of ischaemia, it is probable that the combination of increased and decreased blood flow is advantageous for the wound healing process. Increased blood flow leads to improved oxygen and nutrient supply to the tissue, as well as improved penetration of antibiotics and the removal of waste products. The reduction in blood flow stimulates angiogenesis, which will promote granulation tissue formation.

If the patient is experiencing pain or if the tissue is poorly vascularised (for example, in diabetic foot ulcers and thin skin transplants), negative pressure may need to be reduced to minimise the risk of ischaemia^{24,54,55}. A negative pressure of -40 mmHg may be a good choice since we know that this will reduce the risk of

Figure 2 Blood flow effects in the wound edge

The effect on blood flow of high (-80 mmHg) (A) and low (-40 mmHg) (B) negative pressure: Close to the wound edge, blood flow decreases (blue) while further from the wound edge, blood flow increases (red). Maximum blood flow effects are obtained at -80 mmHg. Reducing the negative pressure to, for example, -40 mmHg reduces the blood-flow effects and the risk of ischaemia. A negative pressure of -40 mmHg may be a suitable pressure for poorly perfused tissue (such as diabetic foot ulcers and thin skin transplants).



ischaemia while maintaining the wound-healing effects⁵¹. Even at a negative pressure of -20 mmHg wound healing can be seen; this is probably the lowest pressure that can be used for NPWT^{21,50}.

What pressure is best for removing large amounts of exudate?

There is seldom any reason to use a negative pressure greater than -80 mmHg^{34,50,51}, but as the drainage of exudate may be improved at -125 mmHg⁵⁰, this pressure level could be used during the initial treatment of highly exuding wounds.

Is the choice of negative pressure level affected by the choice of wound interface dressing (foam or gauze)?

The interactions between pressure and interface are only now beginning to be understood. It is a common misconception that a wound filled with foam should be treated at -125 mmHg and one with gauze should be treated at -80 mmHg. Recent evidence clearly indicates that the level of negative pressure may be tailored depending on the risk of ischaemia^{24,51,54,55} and patient pain^{37,48} and that the choice of interface may be based on the desired effects on granulation tissue formation^{21,34,42}.

Further investigations are needed to explore the true nature of how the wound interface and negative pressure levels affect healing.

What is the difference between continuous, intermittent and variable negative pressure?

Continuous negative pressure is currently the most commonly used

NPWT setting. The pressure level is kept constant at, for example, -80 mmHg. If the negative pressure is repeatedly switched on and off (for example alternating between 0 and -80 mmHg), this is called **intermittent** pressure therapy.

Intermittent pressure therapy is not often used clinically as the sudden spiking of negative pressure changes causes the wound filler to expand and contract repeatedly over the granulation tissue, causing pain for the patient.

Variable pressure therapy has been introduced to provide smooth cycling between two different levels of negative pressure (for example -10 and -80 mmHg), thereby maintaining the negative pressure environment throughout the therapy⁵⁶. In preclinical models, both intermittent and variable NPWT have resulted in massive stimulation of granulation tissue formation in the wound bed^{6,57}. This may be a result of both mechanically stimulating the wound bed (a massaging effect)⁵⁷ and enhanced blood flow, which may enhance tissue oxygenation and angiogenesis⁵⁸.

The future use of NPWT

Although the efficacy of NPWT needs further investigation⁵⁹, this advanced wound care treatment continues to attract the attention of the majority of clinicians involved in caring for patients with wounds. Understanding the role of the wound interface, the level of pressure and its settings is part of the process of optimising the benefits of this treatment modality for patients.

This article was supported by Smith & Nephew.

Summary

The NPWT setting should be tailored to the individual wound for optimal effects. The type of dressing that is in direct contact with the wound (the wound interface) is important for the outcome. The wound interface may be foam, gauze or a wound contact layer. The negative pressure level and vacuum setting (continuous, intermittent or variable negative pressure) may also be adjusted. Rapid advancement in the field of NPWT is anticipated as new wound fillers are developed and their use explored, and clinical data on different NPWT settings are gathered.

To cite this publication

Malmsjö M, Borgquist O. NPWT Settings and Dressing Choices Made Easy. *Wounds International* 2010; 1(3): Available from <http://www.woundsinternational.com>

Author details

Malmsjö M, MD, PhD
Borgquist O, MD
Clinical Sciences, Lund, Lund University, Sweden

Correspondence to: malin.malmsjo@med.lu.se

References

1. Argenta LC, Morykwas MJ, Marks MW, et al. Vacuum-assisted closure: state of clinic art. *Plast Reconstr Surg* 2006; 117(suppl 7): 1275-1425.
2. Banwell P, Téot L. Topical negative pressure (TNP): the evolution of a novel wound therapy. *J Tissue Viability* 2006; 16(1): 16-24.
3. Chariker ME, Jeter KF, Tintle TE, Ottisford JE. Effective management of incisional and cutaneous fistulae with closed suction wound drainage. *Contemp Surg* 1989(34): 59-63.
4. Miller MS, Lowery CA. Negative pressure wound therapy: 'a rose by any other name'. *Ostomy Wound Manage* 2005; 51(3): 44-6, 48-9.
5. Argenta LC, Morykwas MJ. Vacuum-assisted closure: a new method for wound control and treatment: clinical experience. *Ann Plast Surg* 1997; 38(6): 563-76; discussion 577.
6. Morykwas MJ, Argenta LC, Shelton-Brown EI, McGuirt W. Vacuum-assisted closure: a new method for wound control and treatment: animal studies and basic foundation. *Ann Plast Surg* 1997; 38(6): 553-62.
7. Bollero D, Carnino R, Risso D, et al. Acute complex traumas of the lower limbs: a modern reconstructive approach with negative pressure therapy. *Wound Repair Regen* 2007; 15(4): 589-94.
8. Stannard JP, Robinson JT, Anderson ER, et al. Negative pressure wound therapy to treat hematomas and surgical incisions following high-energy trauma. *J Trauma* 2006; 60(6): 1301-6.
9. Scherer LA, Shiver S, Chang M, et al. The vacuum assisted closure device: a method of securing skin grafts and improving graft survival. *Arch Surg* 2002; 137(8): 930-3; discussion 933-4.
10. Joseph E, Hamori C, Bergman S, et al. A new prospective randomized trial of vacuum assisted closure versus standard therapy of chronic nonhealing wounds. *Wounds* 2000; 12: 60-7.
11. Vuerstaek JD, Vainas T, Wuite J, et al. State-of-the-art treatment of chronic leg ulcers: A randomized controlled trial comparing vacuum-assisted closure (V.A.C.) with modern wound dressings. *J Vasc Surg* 2006; 44(5): 1029-37; discussion 1038.
12. Armstrong DG, Lavery LA, Diabetic Foot Study Consortium. Negative pressure wound therapy after partial diabetic foot amputation: a multicentre, randomised controlled trial. *Lancet* 2005; 366(9498): 1704-10.
13. Kamolz LP, Andel H, Haslik W, et al. Use of subatmospheric pressure therapy to prevent burn wound progression in human: first experiences. *Burns* 2004; 30(3): 253-8.
14. Ozturk E, Ozguc H, Yilmazlar T. The use of vacuum assisted closure therapy in the management of Fournier's gangrene. *Am J Surg* 2009; 197(5): 660-5; discussion 665.
15. Wild T, Stortecky S, Stremitzer S, et al. [Abdominal dressing -- a new standard in therapy of the open abdomen following secondary peritonitis?] [Article in German]. *Zentralbl Chir* 2006; 131(suppl 1): S111-4.
16. Gustafsson RI, Sjögren J, Ingemansson R. Deep sternal wound infection: a sternal-sparing technique with vacuum-assisted closure therapy. *Ann Thorac Surg* 2003; 76(6): 2048-53; discussion 2053.
17. Sjögren J, Gustafsson R, Nilsson J, Malmsjö M, Ingemansson R. Clinical outcome after poststernotomy mediastinitis: vacuum-assisted closure versus conventional treatment. *Ann Thorac Surg* 2005; 79(6): 2049-55.
18. Banwell PE. Topical negative pressure therapy in wound care. *J Wound Care* 1999; 8(2): 79-84.
19. Morykwas MJ, Simpson J, Pungner K, et al. Vacuum-assisted closure: state of basic research and physiologic foundation. *Plast Reconstr Surg* 2006; 117(suppl 7): 1215-65.
20. Lu X, Chen S, Li X, et al. The experimental study of the effects of vacuum-assisted closure on edema and vessel permeability of the wound. *Chin J Clin Rehab* 2003; 7: 1244-5.
21. Borgquist O, Ingemansson R, Malmsjö M. Micro- and macromechanical effects on the wound bed by negative pressure wound therapy using gauze and foam. *Ann Plast Surg* In press.
22. Malmsjö M, Ingemansson R, Martin R, Huddleston E. Negative-pressure wound therapy using gauze or open-cell polyurethane foam: similar early effects on pressure transduction and tissue contraction in an experimental porcine wound model. *Wound Repair Regen* 2009; 17(2): 200-5.
23. Saxena V, Hwang CW, Huang S, et al. Vacuum-assisted closure: microdeformations of wounds and cell proliferation. *Plast Reconstr Surg* 2004; 114(5): 1086-96; discussion 1097-8.
24. Kairinos N, Voogd AM, Botha PH, et al. Negative-pressure wound therapy II: negative-pressure wound therapy and increased perfusion. Just an illusion? *Plast Reconstr Surg* 2009; 123(2): 601-12.
25. Wackenfors A, Gustafsson R, Sjogren J, et al. Blood flow responses in the peristernal thoracic wall during vacuum-assisted closure therapy. *Ann Thorac Surg* 2005; 79(5): 1724-30; discussion 1730-1.
26. Wackenfors A, Sjogren J, Gustafsson R, et al. Effects of vacuum-assisted closure therapy on inguinal wound edge microvascular blood flow. *Wound Repair Regen* 2004; 12(6): 600-6.
27. Chen SZ, Li J, Li XY, Xu LS. Effects of vacuum-assisted closure on wound microcirculation: an experimental study. *Asian J Surg* 2005; 28(3): 211-7.
28. Greene AK, Puder M, Roy R, et al. Microdeformational wound therapy: effects on angiogenesis and matrix metalloproteinases in chronic wounds of 3 debilitated patients. *Ann Plast Surg* 2006; 56(4): 418-22.
29. Wilkes R, Zhao Y, Kieswetter K, Haridas B. Effects of dressing type on 3D tissue microdeformations during negative pressure wound therapy: a computational study. *J Biomech Eng* 2009; 131(3): 031012.
30. Yager DR, Nwomeh BC. The proteolytic environment of chronic wounds. *Wound Repair Regen* 1999; 7(6): 433-41.
31. Armstrong DG, Jude EB. The role of matrix metalloproteinases in wound healing. *J Am Podiatr Med Assoc* 2002; 92(1):12-8.
32. Blakely M, Weir D. The innovative use of Safetac soft silicone in conjunction with negative pressure wound therapy: three case studies. Poster presented at the 20th Symposium on Advanced Wound Care (SAWC), Tampa, Florida, 2007.
33. Dunbar A, Bowers DM, Holderness H Jr. Silicone net dressing as an adjunct with negative pressure wound therapy. *Ostomy Wound Manage* 2005; 51(suppl 11A): 21-2.
34. Borgquist O, Gustafsson L, Ingemansson R, et al. Tissue ingrowth into foam but not into gauze during negative pressure wound therapy. *Wounds* 2009; 21(11): 302-9.
35. Malmsjö M, Ingemansson R. Tissue trauma and pain during NPWT and wound filler removal (foam and gauze) – examined by

- immunohistochemistry for substance P and CGRP. Abstract presented at the Symposium on Advanced Wound Care and the Wound Healing Society Meeting in Orlando, Florida, 17-20 April 2010.
36. Franczyk M, Lohman RF, Agarwal JP, et al. The impact of topical lidocaine on pain level assessment during and after vacuum-assisted closure dressing changes: a double-blind, prospective, randomized study. *Plast Reconstr Surg* 2009; 124(3): 854-61.
 37. Krasner DL. Managing wound pain in patients with vacuum-assisted closure devices. *Ostomy Wound Manage* 2002; 48(5): 38-43.
 38. Paglinawan R, Colic M, Simon M. A comparative study of the influence of different pressure levels combined with various wound dressings on negative pressure wound therapy driven wound healing. Presented at a meeting of the European Tissue Repair Society, Malta, September 2008.
 39. Jones SM, Banwell PE, Shakespeare PG. Interface dressings influence the delivery of topical negative-pressure therapy. *Plast Reconstr Surg* 2005; 116(4): 1023-8.
 40. Petzina R, Ugander M, Gustafsson L, et al. Hemodynamic effects of vacuum-assisted closure therapy in cardiac surgery: assessment using magnetic resonance imaging. *J Thorac Cardiovasc Surg* 2007; 133(5): 1154-62.
 41. Campbell PE, Smith GS, Smith JM. Retrospective clinical evaluation of gauze-based negative pressure wound therapy. *Int Wound J* 2008; 5(2): 280-6.
 42. Fraccalvieri M. Negative pressure wound therapy using the gauze and the foam: immunohistological and ultrasonography morphological analysis of the granulation tissue and the scar tissue. Preliminary report of a clinical study presented at the 3rd Congress CORTE 4-6 March 2010. Available from: <http://www.corteitalia.org/> (accessed April).
 43. Zannis J, Angobaldo J, Marks M, et al. Comparison of fasciotomy wound closures using traditional dressing changes and the vacuum-assisted closure device. *Ann Plast Surg* 2009; 62(4): 407-9.
 44. Jeffery S. Advanced wound therapies in the management of severe military lower limb trauma: a new perspective. *Eplasty* 2009; 9: e28.
 45. Chariker ME, Gerstle TL, Morrison CS. An algorithmic approach to the use of gauze-based negative-pressure wound therapy as a bridge to closure in pediatric extremity trauma. *Plast Reconstr Surg* 2009; 123(5): 1510-20.
 46. Sjogren J, Gustafsson R, Koul B, Ingemansson R. Selective mediastinal tamponade to control coagulopathic bleeding. *Ann Thorac Surg* 2003; 75(4): 1311-3.
 47. World Union of Wound Healing Societies. *Principles of best practice: Vacuum assisted closure: recommendations for use: A consensus document*. London: MEP Ltd, 2008.
 48. McCord SS, Naik-Mathuria BJ, Murphy KM, et al. Negative pressure therapy is effective to manage a variety of wounds in infants and children. *Wound Repair Regen* 2007; 15(3): 296-301.
 49. Morykwas M. Sub-atmospheric pressure therapy: research evidence. Presented at the First International Topical Negative Pressure Therapy ETRS Focus Group Meeting. London: ETRS; 2003; 39-44.
 50. Borgquist O, Ingemansson R, Malmjö M. The influence of low and high pressure levels during negative pressure wound therapy on wound contraction and fluid evacuation. *Wound Repair Regen* In press.
 51. Borgquist O, Ingemansson R, Malmjö M. Wound edge microvascular blood flow during negative-pressure wound therapy: examining the effects of pressures from -10 to -175 mmHg. *Plast Reconstr Surg* 2010; 125(2): 502-9.
 52. Nease C. Using low pressure, negative pressure wound therapy for wound preparation and the management of split-thickness skin grafts in three patients with complex wounds. *Ostomy Wound Manage* 2009; 55(6): 32-42.
 53. Malmjö M, Ingemansson R, Martin R, Huddleston E. Wound edge microvascular blood flow: effects of negative pressure wound therapy using gauze or polyurethane foam. *Ann Plast Surg* 2009; 63(6): 676-81.
 54. Kairinos N, Solomons M, Hudson DA. Negative-pressure wound therapy I: the paradox of negative-pressure wound therapy. *Plast Reconstr Surg* 2009; 123(2): 589-98; discussion 599-600.
 55. Kairinos N, Solomons M, Hudson DA. The paradox of negative pressure wound therapy - in vitro studies. *J Plast Reconstr Aesthet Surg* 2010; 63(1): 174-9.
 56. Eberlein T, Fendler H. Using a new technique of negative pressure wound therapy (NPWT), variable pressure therapy (VPT), for the management of chronic, non-healing wounds. Presented at the Symposium for Advanced Wound Care (SAWC), Dallas, Texas, April 2009.
 57. Malmjö M, Ingemansson R. Variable, intermittent and continuous negative pressure wound therapy using foam or gauze: the biological effects on the wound bed including, blood flow, micro and macrodeformation, granulation tissue quantity, wound bed characteristics and tissue ingrowth into the wound filler. Abstract presented at the Symposium on Advanced Wound Care and the Wound Healing Society Meeting in Orlando, Florida, 17-20 April 2010.
 58. Borgquist O, Ingemansson R, Malmjö M. The effect of intermittent and variable negative pressure wound therapy on wound edge microvascular blood flow. *Ostomy Wound Manage* 2010; 56(3): 60-7.
 59. Ubbink DT, Westerbos SJ, Nelson EA, Vermeulen H. A systematic review of topical negative pressure therapy for acute and chronic wounds. *Br J Surg* 2008; 95(6): 685-92.

Further reading

Malmjö M, Ingemansson R, Sjögren J. Mechanisms governing the effects of vacuum-assisted closure in cardiac surgery. *Plast Reconstr Surg* 2007; 120(5):1266-75.

For additional resources please visit www.woundsinternational.com or www.wounds-uk.com