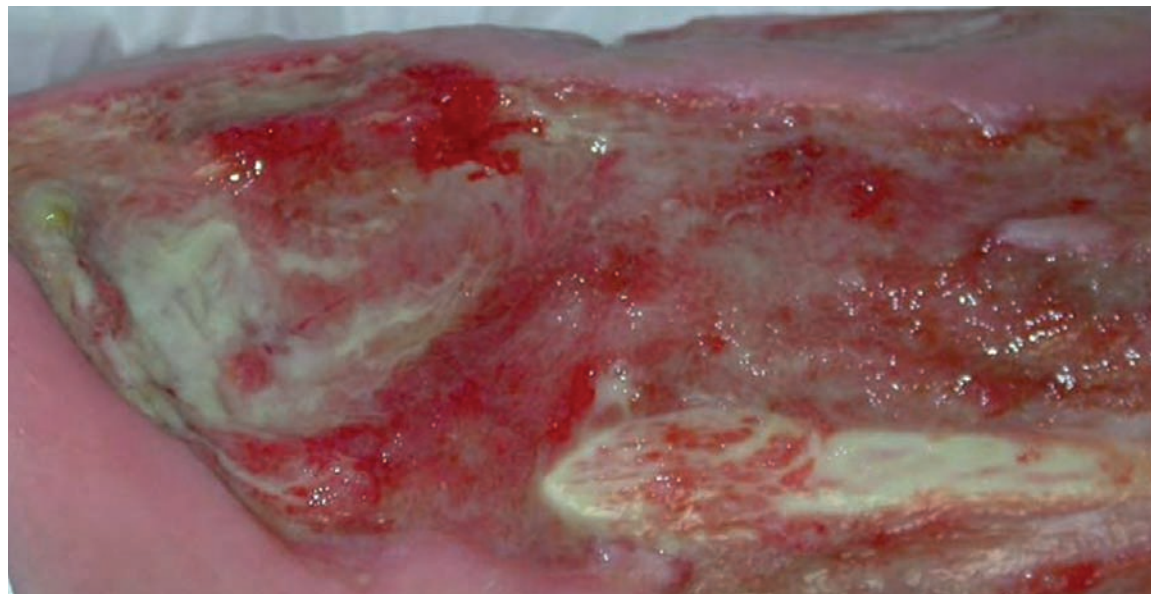


## Chronic arterial leg ulcer with MRSA

Astrid Probst



# Chronic arterial leg ulcer with MRSA

## Diagnoses

- Bilateral stage IV peripheral arterial occlusive disease (pAOD) with chronic ulceration of both lower legs
- Bilaterally infected chronic leg ulcer, MRSA positive
- Type II diabetes mellitus with diabetic polyneuropathy
- Heart failure and cardiac arrhythmias

## Medical history and findings on admission

The 92-year-old patient has been suffering from ulceration of both lower legs for about a year. She sought readmission to our hospital due to a marked deterioration in the bilateral ulceration associated with known pAOD.

The patient is suffering from insulin-dependent diabetes mellitus, bilateral pAOD and cardiac insufficiency. Therefore, surgical treatment was ruled out. The wound swab specimens on admission to hospital showed heavy colonisation with *E. coli*, *Staph. aureus* and MRSA.

## Procedure

The treatment of chronic leg ulcers is always a major challenge for us wound managers, especially when surgical interventions cannot be considered because of the patient's poor general condition. In addition, the reduced tissue blood flow associated with pAOD creates the constant risk of necroses or infections developing.

In the case reported we tested the non-medicated, antimicrobial Cutimed® Sorbact® wound dressing for the first time in a patient with a leg ulcer colonised with MRSA. We monitored the infection status of

the wounds by continuously taking wound swabs for microbiological analysis. We also documented the course of wound healing and the general condition of the 92-year-old patient. For physical relief the patient did not receive additional antibiotic therapy and was continuously monitored by our trained staff on the ward. The Cutimed® Sorbact® dressing was changed every two days and the wounds were irrigated with antiseptic solution (Octenisept®, Schülke & Mayr).

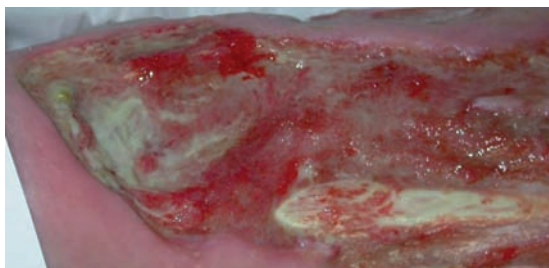
## Summary

After eight days of treatment with Cutimed® Sorbact®, no MRSA was detectable any longer in the ulcers. *E. coli* and *Staph. aureus* were also successfully removed from the wounds. This microbiological finding was confirmed for both lower legs in further swab specimens taken on days 11 and 12.

Overall, a marked decrease in the infection signs was observed during the course of treatment. Besides the measurable microbial reduction, especially the decrease in wound odour and a diminution of the redness of the wound margins and periwound skin were positive features. Because of the rapid wound cleansing observed during the Cutimed® Sorbact® treatment and the improved course of healing achieved with the conservative therapeutic concept, the patient was discharged to ambulatory care after a hospitalisation period of 14 days. Continued treatment with Cutimed® Sorbact® was recommended.

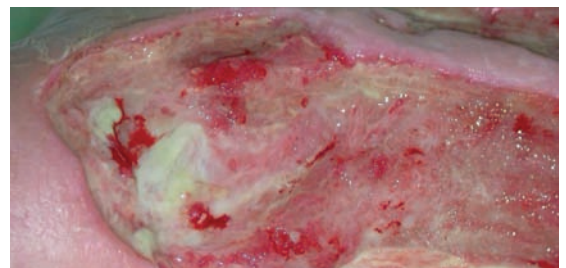
Four months later, control wound swabs taken in the hospital confirmed the positive course of healing of the ulcers on both legs. MRSA was not detected any more.

## Right lower leg



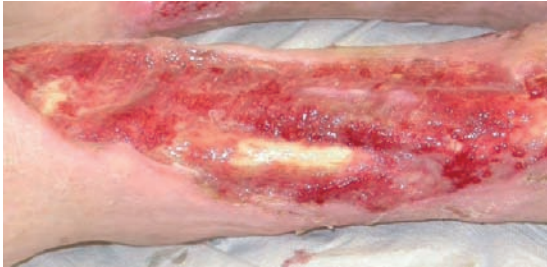### Day 1

The wound bed is covered with a layer of fibrinous necrotic debris. The wound margins are reddened and show signs of infection. Heavy exudation and an unpleasant odour also suggest the presence of an infection. A wound swab confirms the suspicion: *E. coli*, *Staph. aureus* and MRSA are abundantly present.



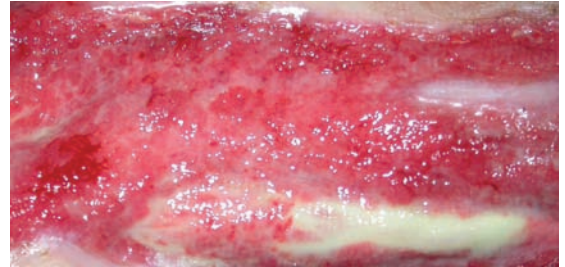
### Day 5

A marked decrease in necrotic debris on the wound surface is observed. The reddening of the wound margins has diminished and increased amounts of granulation tissue are visible. The wound swab shows reduced colonisation with *E. coli*, *Staph. aureus* and MRSA. Because of the decreasing exudation, Cutimed® Sorbact® is used in combination with hydrogel.



#### Day 11

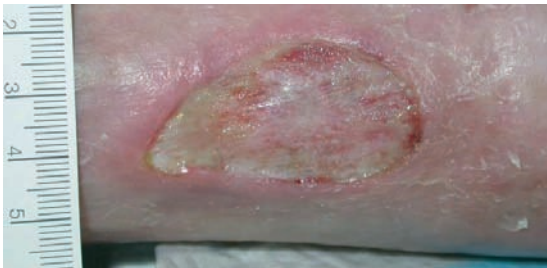Two wound swabs taken in the last two days confirmed the findings of day 5. Neither *E. coli*, *Staph. aureus* nor MRSA were detectable. Wound cleanup has been achieved. The picture shows that the wound is free from necrotic debris. Granulation and epithelial tissue are developing and increasing, and the wound size is decreasing.



#### Day 14

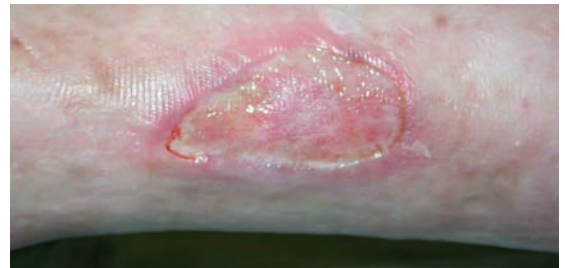Granulation and epithelial tissue have markedly increased and the wound is closing. The redness, wound odour and bacterial colonisation have receded during therapy, indicating a positive healing process that now allows the transition to outpatient care.

### Left lower leg



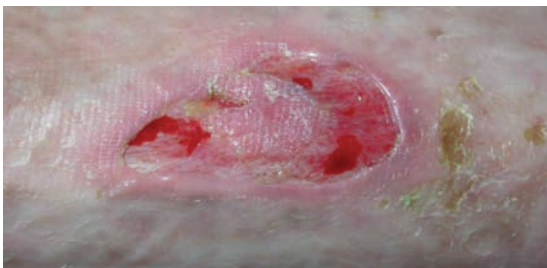#### Day 1

The wound bed is covered by a layer of fibrinous necrotic debris. High rate of exudation, unpleasant odour and reddened wound margins and periwound skin indicate the presence of an infection. The wound swab confirms the presence of abundant *E. coli* and moderate amounts of MRSA.



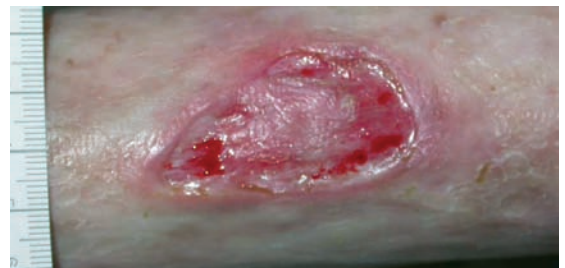#### Day 5

Transition from the inflammatory phase to granulation. The reddening of the wound margins and periwound skin has decreased. Necrotic wound debris has also been removed and an increase in granulation tissue is visible. The wound swab is already negative on this day. Further swabs will be taken on the following days to confirm this result.



#### Day 11

Two wound swabs taken on the last two days confirmed the results of day 5: no evidence of *E. coli* and MRSA. Wound cleanup has been accomplished. A marked improvement in the wound status is observed on inspection. With the exudation decreasing, granulation tissue is increasing. No wound odour.



#### Day 14

We observe an increase in granulation tissue. Exudation is markedly reduced. The reddening of the wound margin and periwound skin has disappeared completely. The wound is free of *E. coli*. Despite residual contamination with MRSA (the wound swab on day 12 showed a small amount of MRSA) the transition to outpatient care can be approved.

**Author**

Astrid Probst, Klinikum am Steinenberg, Steinenbergstr. 31, D-72764 Reutlingen, Germany

Note:  
The product name Cutisorb® Sorbact® was changed to Cutimed® Sorbact® in 2008. The case reports were performed using Cutisorb® Sorbact® swabs and absorbent pads.